


# Caries presentation in illicit drug users and excessive soft drink consumers

IUSD Department of Endodontics

E. Parker; Y. Ehrlich; D, Pfothauer; J. Bringas; N. Warner



## Abstract

**Aim:** Advanced cervical caries in anterior teeth is common to two different patient behaviors. Rampant cervical caries (“meth mouth”) is a common presentation in drug users. Extensive consumption of soft drinks also presents a similar pattern of cervical caries. Two cases are presented and dental treatment considerations are discussed.

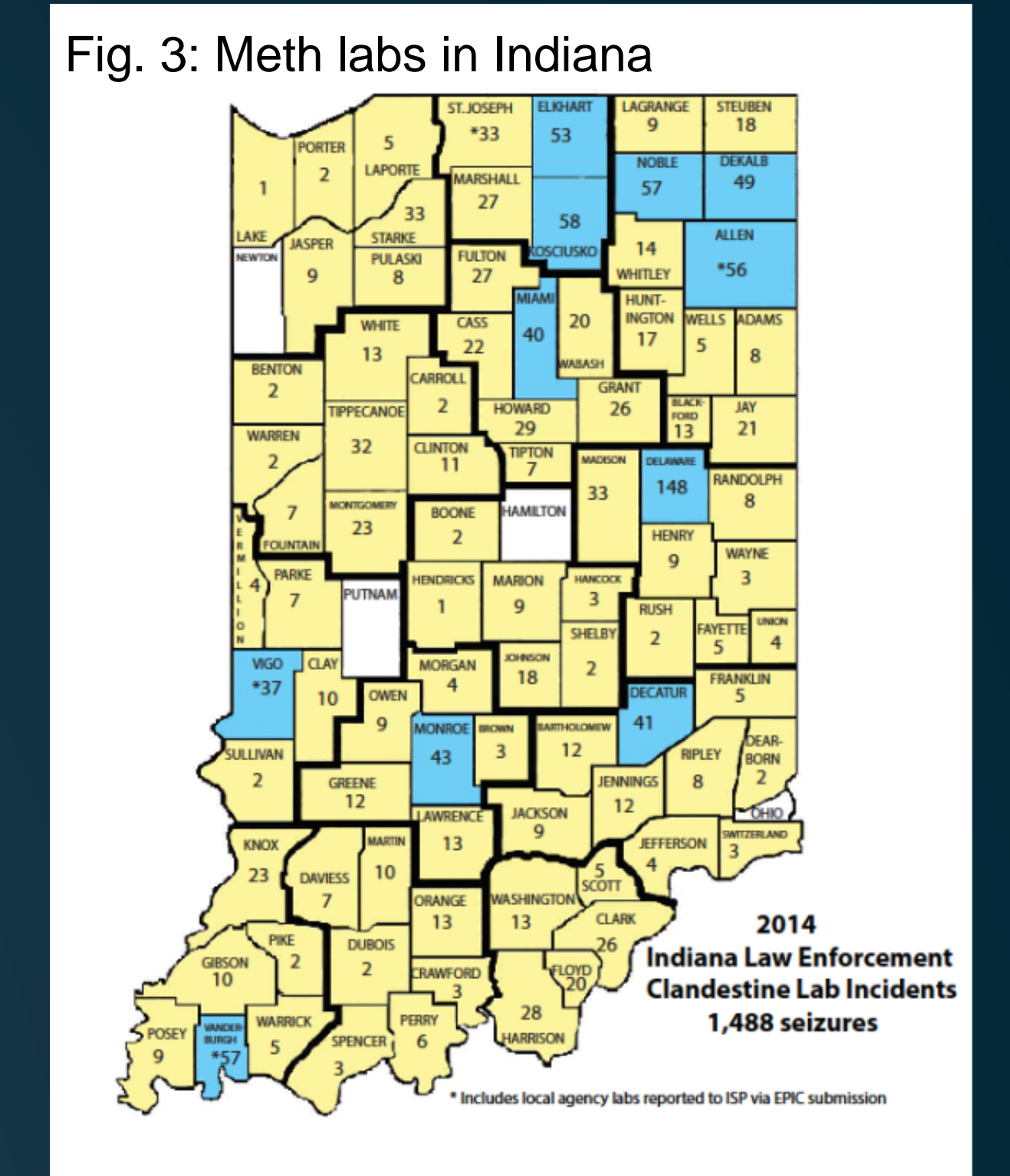
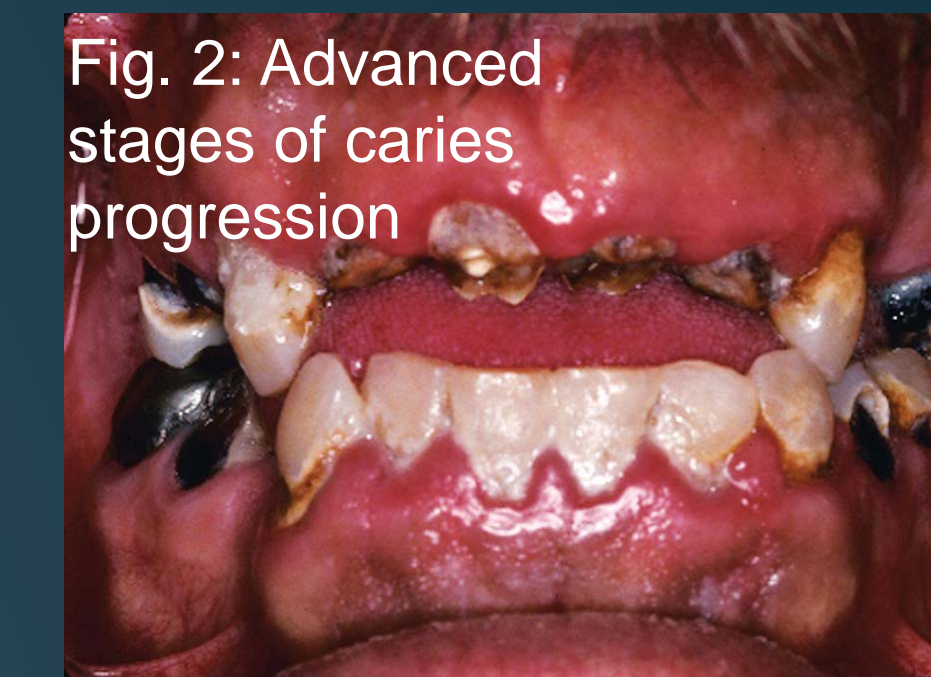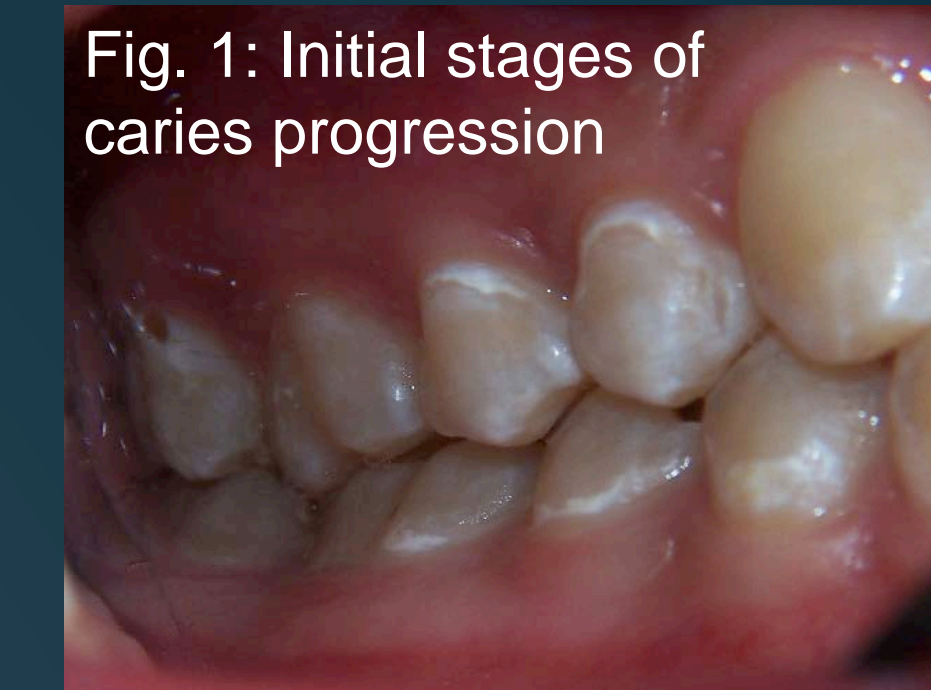
### Key learning points

- Illicit drug users often present with moderate-severe anterior cervical decay.
- Excessive consumers of soft drinks also may present with moderate-severe anterior cervical decay.
- Develop awareness of both illicit drugs and excessive soft drink consumption as part of the etiology of moderate-severe anterior cervical caries

## Introduction

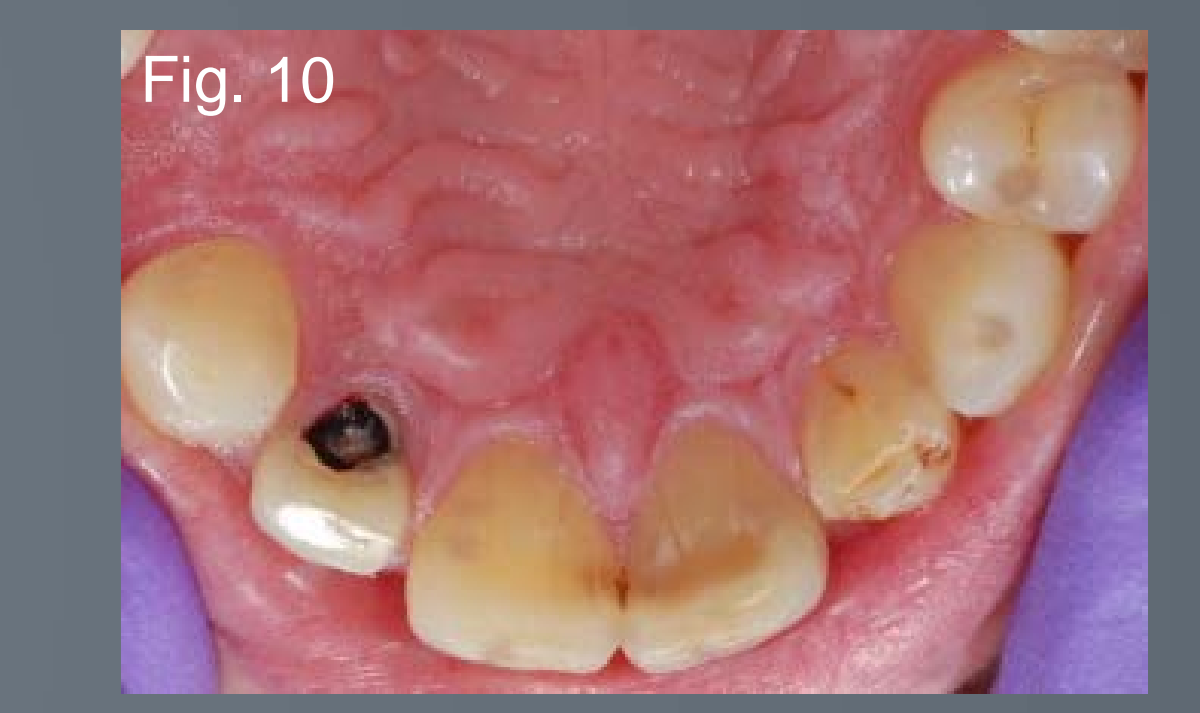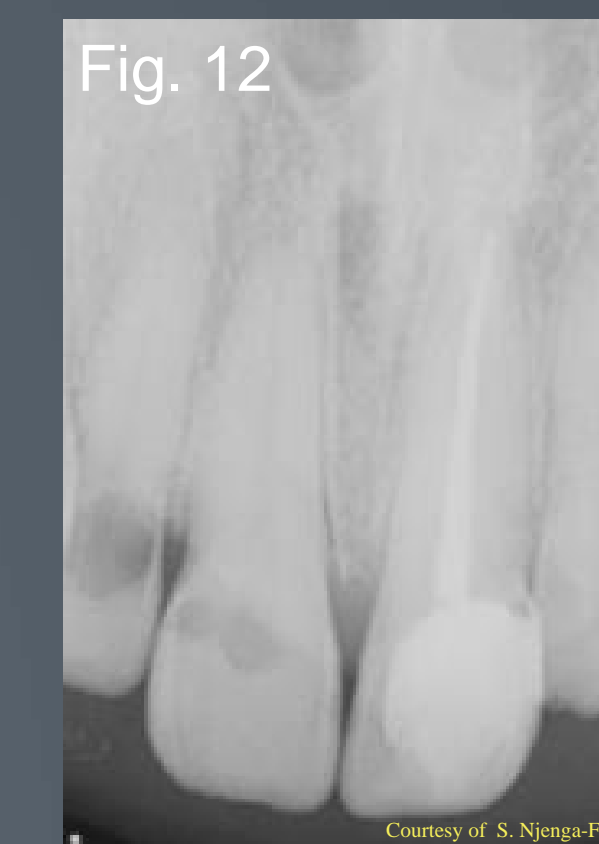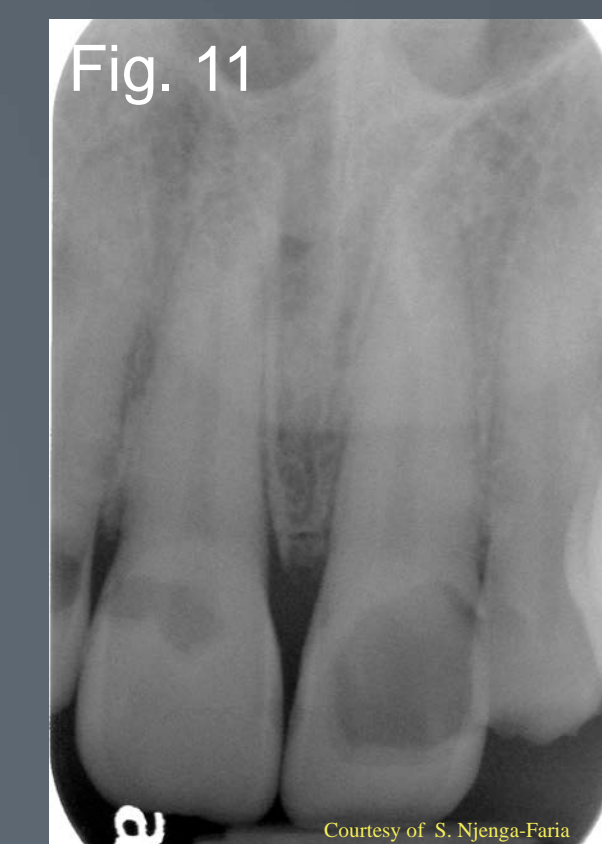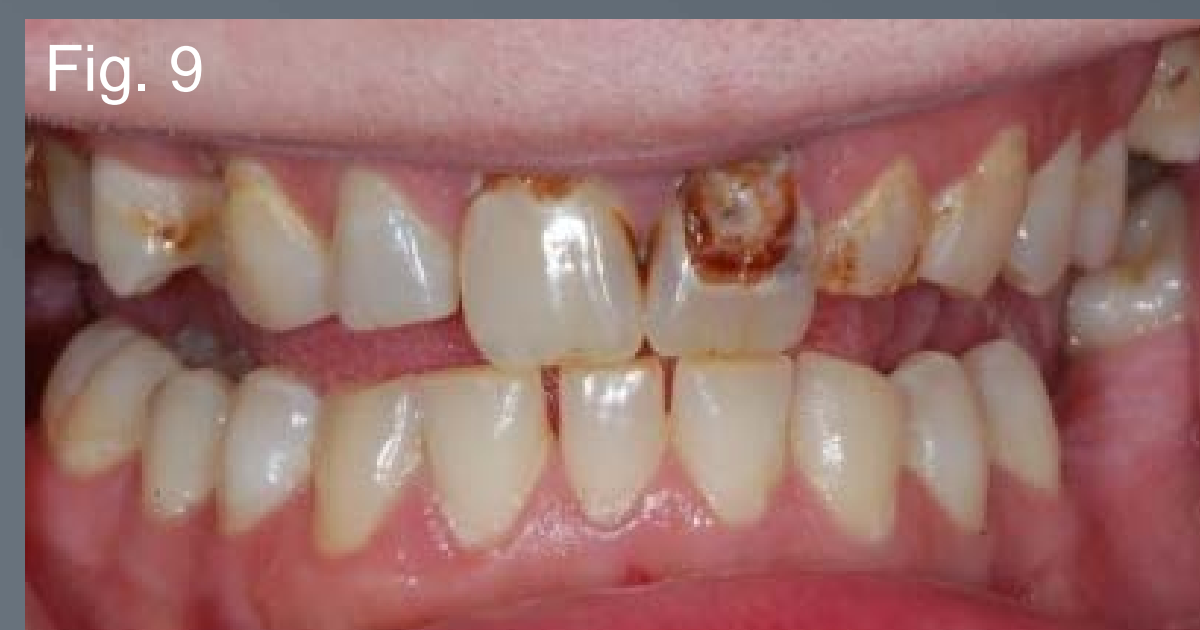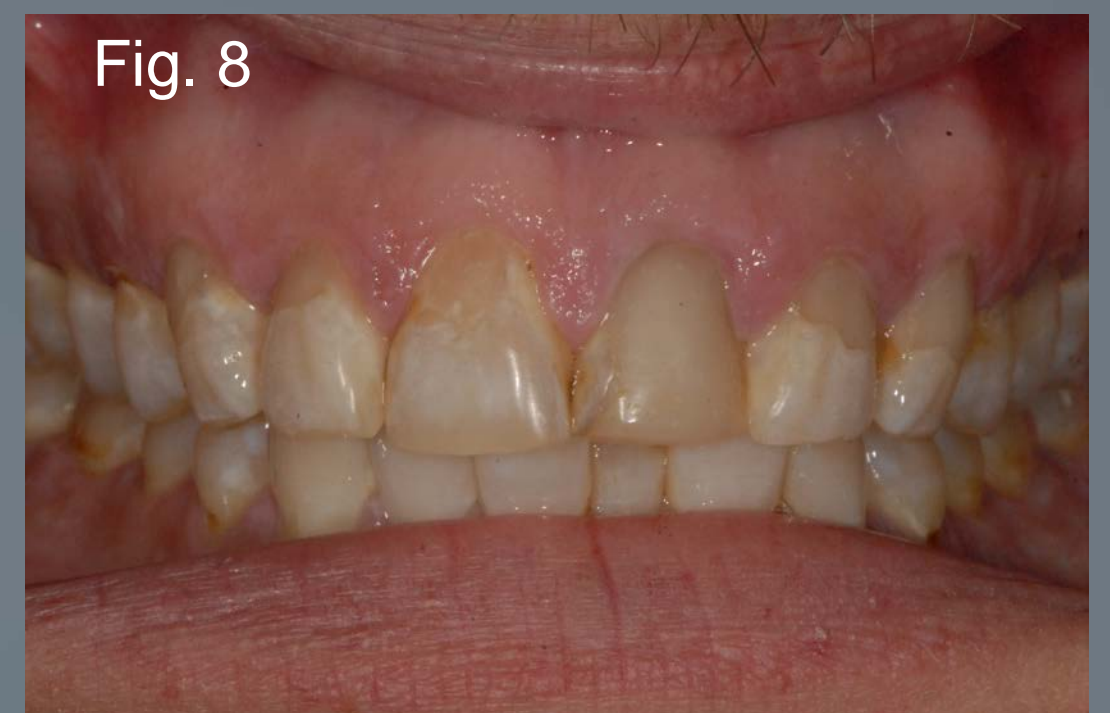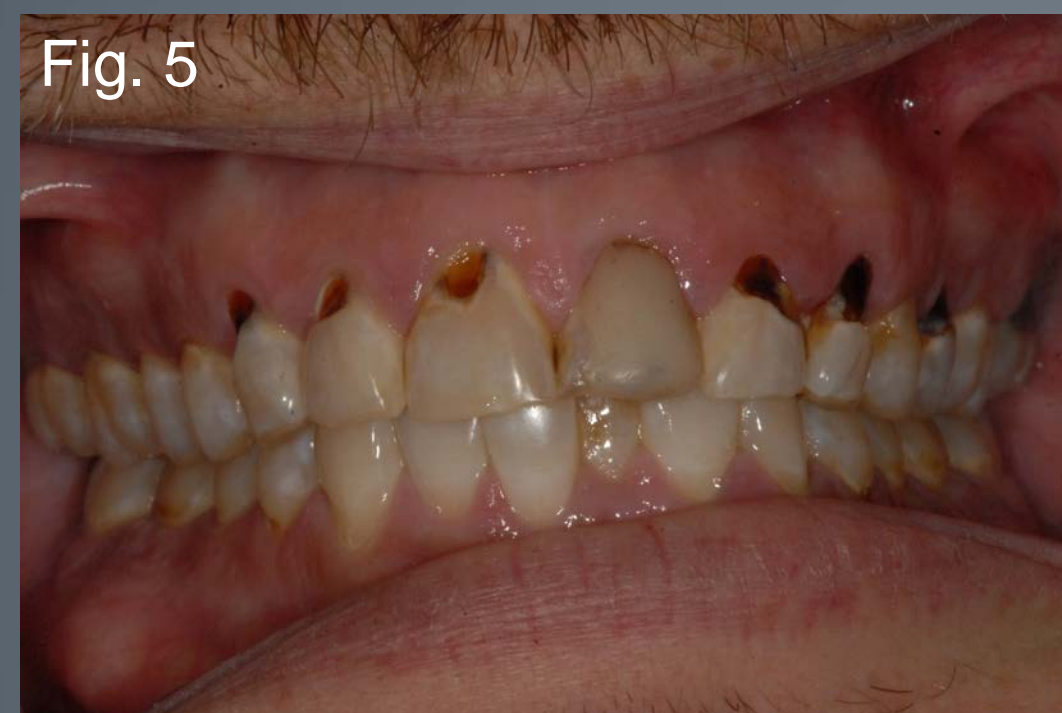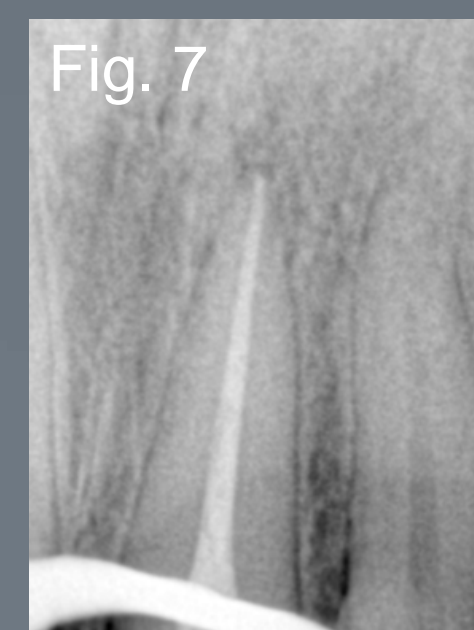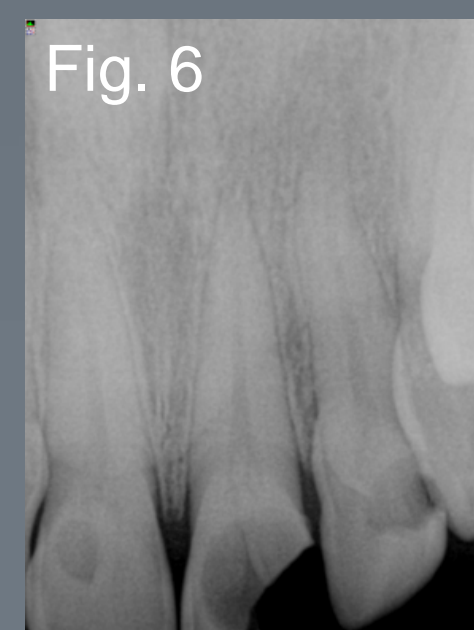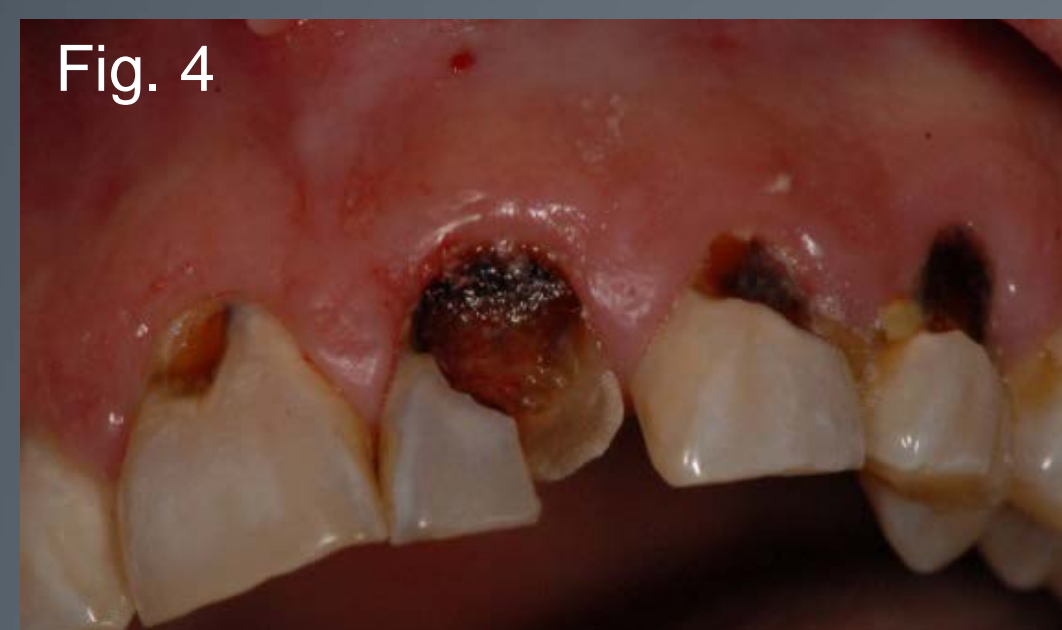Methamphetamine/cocaine use is reaching epidemic levels in Midwestern states, including Indiana who led the nation in 2014 in meth lab seizures, due to increased availability of “meth” and its readily-available precursors. (Fig. 3) Soft drinks continue to also be readily available and are easily and frequently abused. Both activities can lead to a progression of dental decay from initial decalcification (Fig. 1) to complete coronal destruction (Fig. 2)

We compared the case of an excessive soft drink consumer with that of an abuser of cocaine and identified their similarities in clinical presentation. Poor diet, poor oral health, and marginal overall health are contributing factors and/or sequelae common to both excessive soft drink consumers and illicit drug users.



**DRINKS DESTROY TEETH**  
A Program of the Indiana Dental Association  
<http://drinksdestroyteeth.org/>

2014\_Indiana\_Meth\_Lab\_Seizures  
Methamphetamine Investigation System  
<http://www.in.gov/meth/2330.htm>



## Case One: Excessive Soft Drink Consumption

### Background:

A young patient presented to IUSD for evaluation and treatment of a painful #9. Clinical exam: #9 had extensive facial and cervical caries with a pulp exposure. Cervical caries on #6,7,8,10,11,12,13. Fig 4, Fig 5 Patient's history revealed frequent daily consumption of multiple sweet soft drinks. #9 had become increasingly painful and that caused patient to seek treatment. Pulpal and Percussion/Palpation testing and radiographic exam of #9 were conducted. Endodontic Dx: #9 Pulpal Necrosis with Symptomatic Apical Periodontitis

**Preventive Treatment:** Oral hygiene(OH) instruction to improve frequency and technique of brushing, flossing. Use of fluoride/antibacterial mouthrinse, and recommendation to reduce the frequency of soft drink consumption.

### Endodontic Treatment:

**First appointment:** Anesthesia obtained (lidocaine 2% w/ epinephrine 1:100k). Caries was removed and endodontic access created. Orifice enlargement with Gates-Glidden #2,3. Canal was shaped and instrumented canal walls with hand instruments to size 40.02. Irrigated with with 6% NaOCl. Intra-canal medicament, Ca(OH)<sub>2</sub> paste (Ultradent) was placed for 14 days. **Second appointment:** Ca(OH)<sub>2</sub> paste removed. Irrigation with 6% NaOCl. Obturated canal using gutta-percha and Roth's sealer using cold lateral compaction method. Access closed with Cavit and IRM.

### Restorative Treatment:

#9 Parapost cemented and Premise composite core buildup. Full coverage crown is planned. Caries in #6,7,8,10,11,12,13 were removed and teeth restored with Premise composite resin restorations. Fig 8 Patient's OH improved and soft drink consumption was reduced.

## Case Two: Cocaine Abuse

### Background:

A young patient presented to IUSD for evaluation and treatment of a painful #9. Clinical exam: #9 had extensive facial and cervical caries with a pulp exposure. Cervical caries on lingual of #10. Severe Dental Attrition of incisor teeth. Fig 4, Fig 10 Patient' reports having used cocaine for many years. #9 had become increasingly painful and that caused patient to seek treatment. Pulpal and Percussion/Palpation testing and radiographic exam of #9 were conducted. Endodontic Dx: : #9 Pulpal Necrosis with Symptomatic Apical Periodontitis

**Preventive Treatment:** Oral hygiene instruction to reduce the frequency of soft drink consumption.

### Endodontic Treatment:

**First Appointment:** Anesthesia obtained with mepivacaine 3% ( no epinephrine). Shaped and instrumented canal walls with hand and rotary instruments (Profiles) to size 40.04. Achieved apical patency. Irrigated with 6% NaOCl. Intra-canal medicament, Ca(OH)<sub>2</sub> paste (Ultradent) was placed for 14 days. **Second Appointment:** Obturated canal using gutta-percha and Roth's sealer using cold lateral compaction method. Access restored with a composite restoration immediately after obturation.

### Restorative Treatment:

Patient did not return to IUSD for continuation of treatment.

## Discussion

These two cases demonstrate the similarities of cervical caries as a result of illicit drug use and excessive soft drink consumption. Both of these problems exist in Indiana.(3,5) Poor diet, poor oral hygiene habits, and a marginal overall health status are also common to patients who abuse illicit drugs and/or soft drinks. Mental health disorders such as depression can lead to patients' abuse of illicit drugs/soft drinks.(1,2,4,6,7,8) A thorough collection of patient history data can identify these aspects. It is important that dental providers take into consideration the potential for a multi-factorial etiology in moderate-severe cervical caries and seek to identify all possible contributing factors when treating such a patient. Dental providers must treat the cause(s) of cervical caries, and the overall health of the patient, in addition to the cervical caries themselves.

## Conclusion

Cervical caries in anterior teeth associated with soft drinks demonstrate similar characteristics to those observed in patients with reported cocaine or methamphetamine abuse. This should alert dental providers to be aware of both illicit drug use and soft drink intake as causes for a patient's clinical presentation of anterior cervical caries along with key factors in the patient's corresponding medical, dental, and social history information .

## References

1. Bassiouny, M. (2013). Dental erosion due to abuse of illicit drugs and acidic carbonated beverages. *General Dentistry*, 38-44.
2. Hildebrandt, G., Tantbirojn, D., Augustson, D., & Guo, H. (2013). Effect of Caffeinated Soft Drinks on Salivary Flow. *Journal of Caffeine Research*, 3(3), 138-142.
3. <http://drinksdestroyteeth.org/>
4. Luebke, A., & Bell, D. (2009). Mountain Dew® or Mountain Don't? A Pilot Investigation of Caffeine Use Parameters and Relations to Depression and Anxiety Symptoms in 5th and 10th-Grade Students. *Journal of School Health*, 79(8), 380-387.
5. Mack JL. Indiana ranks No. 1 in meth lab seizures. In: IndyStar. <http://www.indystar.com/story/news/crime/2014/04/01/indiana-ranks-meth-lab-seizures/7177031/>; 2014.
6. Morio, K., Marshall, T., Qian, F., & Morgan, T. (2008). Comparing diet, oral hygiene and caries status of adult methamphetamine users and nonusers: A pilot study. *Journal of the American Dental Association*, 139, 171-176.
7. Rusyniak, D. (2011). Neurologic Manifestations of Chronic Methamphetamine Abuse. *Psychiatric Clinics of North America*, 29(3), 261-275.
8. Shaner, J., Kimmes, N., Saini, T., & Edwards, P. (2006). "Meth Mouth": Rampant Caries In Methamphetamine Abusers. *AIDS PATIENT CARE and STDs*, 20(3), 146-150.